

# ADVANTAGES OF MINIMALLY INVASIVE SPINE SURGERY FOR THE TREATMENT OF THORACOLUMBAR FRACTURES: A SYSTEMATIC REVIEW

Arfan Surya Adhitama<sup>\*</sup>, Rieva Ermawan<sup>2</sup>

<sup>1</sup>Faculty of Medicine, Sebelas Maret University, Surakarta, Indonesia

<sup>2</sup>Department Orthopaedia and Traumatology, Dr. Moewardi General Hospital, Faculty of Medicine, Sebelas Maret University,  
Email : arfansuryaadhitama@gmail.com

## ABSTRACT

**Background:** Thoracolumbar spine fractures are the most common vertebral fractures. Trauma to the thoracolumbar spine can cause disability, spinal deformity, neurological deficits, psychological, economic and social problems. Safe and effective treatment is very important. Currently, the miss approach is only used for the management of type A (AO classification) and stable thoracolumbar fractures.

**Objective:** this systematic review aims to determine the advantages of using the miss approach compared to the open approach in the treatment of thoracolumbar fractures.

**Method:** Using a systematic review method, this study searches for literature that matches the criteria in the PubMed electronic database and the wiley online library. There are 644 samples (290 samples of the MISS approach and 354 samples of the open approach) from seven articles that match the criteria that we have determined. Next, we extract data from our entire sample to find out the advantages of the MISS approach.

**Results:** The MISS approach provides advantages in intraoperative (reduced operating time and blood loss) and early postoperative (reduced VAS score and hospitalization). In addition, the MISS approach also has advantages in the form of: minimal CSA, low transfusion requirements, and has a good ODI score. After more than one year of follow-up, the miss approach had the same neurologic recovery and risk of complications as the open approach.

**Conclusion:** A minimally invasive approach provides an advantageous and safer to the management of all types of thoracolumbar fractures.

**Keywords:** Advantage, Minimally Invasive, Open Surgery, Thoracolumbar Injuries

---

## BACKGROUND

Thoracolumbar spine fractures are the most common fractures of the spinal column. This accounts for 67% spinal injury.<sup>1,2</sup> This trauma is mainly among young adults and elderly in cities.<sup>3</sup> Thoracolumbar spinal trauma can cause disability, spinal

deformity and neurological deficits. In the long term this trauma can have an impact on psychological, economic and social.<sup>4</sup> The AO spine thoracolumbar classification system categorizes thoracic and lumbar spine injuries into three major types, ranked by increasing degree of instability: type A

(compression fracture), B (tension band injury), and C (dislocation).<sup>2,5</sup> Most thoracolumbar fractures require surgical intervention.<sup>1</sup> Surgical intervention depends on the degree of spinal instability.<sup>1,4</sup> Stable thoracolumbar fractures can generally be treated conservatively.<sup>2</sup>

Surgery aims to reduce the deformity, restore the canal anatomy and consolidate the vertebral fracture.<sup>6</sup> The open method is the traditional treatment for thoracolumbar fractures.<sup>7,8</sup> Open reduction and instrumented fusion, which may restore some degree of stability at the treated levels, has traditionally been regarded as the gold standard surgical method for repairing spinal fractures.<sup>9</sup> This method is quite invasive and uses a long incision.<sup>10</sup> On the other hand, this method causes intraoperative trauma and several other complications.<sup>10,11,12</sup> therefore not all patients can tolerate this approach.<sup>6</sup>

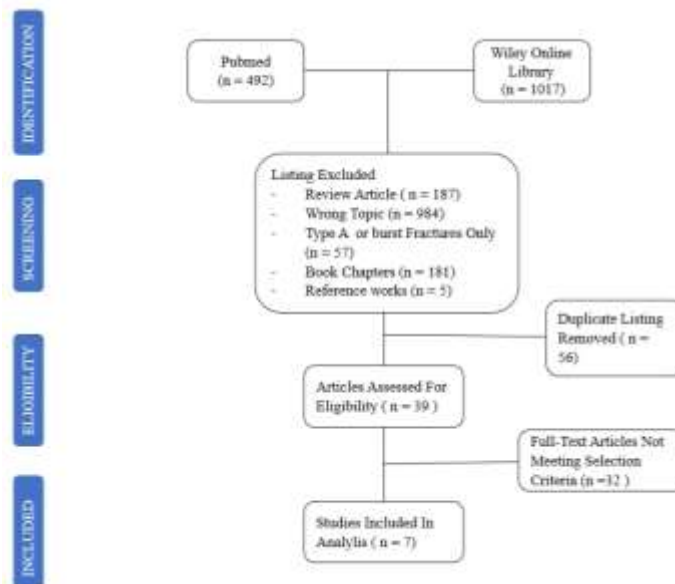
Currently, patient safety and treatment effectiveness are importance. A practitioner should do the most profiable management. In the last decade the use of the MISS approach for the treatment of thoracolumbar fractures has increased.<sup>13</sup> Minimally invasive procedures have been presented in some case reports for the surgical treatment of AO Spine types fractures (A, B and C) and unstable fracture, using percutaneous pedicle screw fixation, with or without facet fusion, to reduce approach-related morbidity, and these also produced clinical results equal to open fusion.<sup>14</sup> However, until now the use of

MISS is more commonly used for stable fractures and type A, some type B AO's Classification. Therefore, this systematic review aims to determine the advantages of using the miss approach compared to the open approach in the treatment of thoracolumbar fractures.

## METHOD

This review used the Preferred Reporting Items for Systematic Reviews. This article search was conducted according to the systematic review reporting items. To search for relevant articles, we used PubMed and Wiley Online Library as electronic databases. We use several keywords and combinations to guide article searches. The following keywords and combinations we used: "thoracolumbar spine fracture", "minimal spine surgery", "percutaneous screw fixation", "open spine surgery".

To ensure the articles are up to date, we conducted a search on articles published between January 2017 to August 2022. In addition, we conducted a manual review of articles. We only use English articles. The number of citations on each article is sorted. Then we screened titles and abstracts for article analysis. We reject duplicate articles. Only articles with full text were analyzed according to the Criteria for this systematic review. **See Figure 1** for the PRISMA flow chart.



**Figure 1.** Literature search strategy based on PRISMA flowchart

## 1. Criteria for Study Selection Eligibility

The criteria we used to collect articles in this systematic review were: articles published in English, undergoing peer review, either a prospective or retrospective in human study, comparing MISS and open spinal surgery for thoracolumbar spinal fractures at least contain one of type B, C or unstable fracture, and the last criterion is comparing at least one desirable outcome (operative time, blood loss, pain intensity assessed using a visual analog scale (VAS) and hospital stay).

## 2. Data analysis

The collected articles then extracted as follows: first author, senior author, data collection method, number of samples, fracture type, comparison and results. The results we extracted included operating time, blood loss, pain intensity assessed using a visual analogue scale (VAS) and

hospital stay and other results that support this systematic review.

## 3. Methodological Quality Evaluation

According to the Oxford Center for Evidence-Based Medicine, all the studies were evaluated for internal validity and given a level of evidence rating

## RESULTS

A total of 1509 articles were found in the search engine database. After screening and assessing eligibility, there were seven articles that matched the criteria in this systematic review. There are six retrospective articles<sup>16-21</sup> and one prospective article<sup>15</sup>. Total found 644 patients, where 290 patients underwent MISS approach and 354 patients underwent open surgery approach to treat thoracolumbar fractures. In general, this study evaluated operative time, intraoperative blood loss, postoperative vas

score, length of hospital stay and other results that support this study (**Table 1**).

In 5 of 7 articles, treatment of thoracolumbar fractures using the MISS approach was significantly faster than the open surgery approach. Comparison of operative time MISS approach vs Open Approach: (122 min Vs 180 min)<sup>16</sup>, (128.3 min Vs 151 min)<sup>17</sup> (109 min Vs 157 min)<sup>19</sup> (60-120 min Vs 90-150 min)<sup>20</sup> (118 min Vs 141 min).<sup>21</sup> One article did not discuss operative time.<sup>15</sup> Lee et al in their study, the difference in operating time was not significant even though the MISS approach had a shorter operating time of 51 minutes (138 min Vs 189 min).<sup>18</sup>

Intraoperative blood loss was significantly less in the management of thoracolumbar fractures using the MISS approach than the open surgery approach. A report of intraoperative blood loss was obtained: (99.3 mL Vs 591.5 mL)<sup>16</sup>, (242.8 mL Vs 437.8 mL)<sup>17</sup>, (136 mL Vs 602 mL)<sup>19</sup>, (83.7 mL Vs 639.4 mL)<sup>20</sup>, (437 mL Vs 862

mL)<sup>21</sup>. 2 of these 7 studies did not report intraoperative blood loss.<sup>15,18</sup>

In the first follow-up after surgery up to 7 days, the pain scale was measured using the VAS score. 5 articles stated that the VAS score on the MISS approach was significantly lower than the open surgery approach, MISS Vs Open Approach: (2.8 Vs 3.9)<sup>15</sup>, (2.5 Vs 3.8)<sup>16</sup>, (2.6 Vs 3.5)<sup>17</sup>, (2-5 Vs 5-10)<sup>20</sup> (3.93 Vs 4.05)<sup>21</sup>. Two other studies did not include VAS scores in the first follow-up after surgery.<sup>18,19</sup>

Significantly shorter hospital stay in the treatment of thoracolumbar fractures using the MISS approach than the open surgery approach. 4 articles reported MISS Vs Open : ( 9.4 d Vs 20.7d)<sup>16</sup>, ( 6.6 d Vs 8.5d)<sup>17</sup>, ( 5.8 d Vs 10.3d)<sup>20</sup>, ( 12.32 d Vs 15.51 d)<sup>21</sup>. 2 articles declared no significant difference between the MISS approach vs the open surgery approach, ( 6 d Vs 9.5 d)<sup>18</sup>, ( 12.4 d Vs 14.3 d)<sup>19</sup>. One article did not report on length of hospital stay.<sup>15</sup>

**Table 1.** Result of the study

STUDY	MISS	OPEN	Level of Evidence	Results		
				Operative Time	Blood Loss	VAS Score In 1 <sup>st</sup> foll-up Post-OP
Junhui et al 2017 <sup>15</sup>	n = 35	n = 40	2	NA	NA	MISS: 2.8 Open: 3.9
Wang et al 2017 <sup>16</sup>	n = 56	n = 49	3	MISS: 122 min Open: 180 min	MISS: 99.3 mL Open: 591.5 mL	MISS: 2.5 Open: 3.8
Zhang et al 2019 <sup>17</sup>	n = 21	n = 29	3	MISS:128.3 min Open: 151min	MISS: 243.8 mL Open: 437.8 mL	MISS: 2.6 Open: 3.5
Lee et al 2019 <sup>18</sup>	n = 13	n = 19	3	MISS: 138 min Open: 189 min	NA	NA
Afolabi et al 2020 <sup>19</sup>	n = 100	n = 155	3	MISS: 109 min Open: 157 min	MISS: 136 mL Open: 602 mL	NA

<b>Younus et al 2020</b> <sup>20</sup>	n = 27	n = 24	3	MISS:60-120 min Open: 90-150 min	MISS: 83.7mL Open: 639.4 mL	MISS: 2-5 Open: 5-10
<b>Wang et al 2022</b> <sup>21</sup>	N = 38	N = 38	3	MISS: 118 min Open: 141 min	MISS: 437 mL Open: 862 mL	MISS: 3.93 Open: 4.05

Results		Conclusion
Hospital Stay	Others	
<b>NA</b>	CSA: with Wiltse, CSA decreased by 7.6% vs 35.4% with posterior open surgery VAS last follow-up: 0.9 vs 1.7	The Wiltse technique effective reduced muscle injury, as well as reduced atrophy, fatty infiltration in the multifidus and reduced post operative VAS up to 1 year follow-up
MISS:9.4 d Open: 20.7d	VAS : 1.9 vs 3.1 (6mo) ODI : 7.2 vs 16 (6mo) VAS, ODI at last follow-up: no difference Postoperative complications and neurological recovery: no difference	MISS more safer because has small incision, minimal blood loss, less hospital stay, significantly lower VAS score and ODI for up to 6 months
MISS: 6.6d Open: 8.5d	Radiographic parameters improved in both groups Relief of canal encroachment: MISS (4.0%vs open 9.1%) VAS : 1.4 vs 2.4 in 1 year follow-up neurological recovery: no difference in 1 year follow-up	MISS reduce iatrogenic trauma and give similar or better outcome
MISS: 6 d Open: 9.5 d	Fluoroscopic dose: MISS 34 mSv vs open 4 mSv Hemoglobin drop: MISS 12 g/L vs open 21 g/L Kyphoticangulation correction: no difference, but with loss of position greater with open surgery (28% vs 96%)	Polyaxial-monoaxial screw combination with MISS construction provides good clinical and radiological results in unstable thoracolumbar and lumbar fractures.
MISS: 12.4d Open: 14.3d	Need for transfusion: MISS 37% less than open surgery Mobilization/complications/mortality: no difference	Miss is available for the treatment of thoracolumbar fractures and provides several benefits such as reduced operating time, blood loss and transfusion
MISS: 5.8 d Open:10.3d	Postoperative complications and neurological recovery: no difference (Last Foll-Up ) Highly significant patient satisfaction in the MISS group (Last Foll-Up )	Significant reduced in length of surgery, blood loss, hospital stay, VAS scores and high satisfaction of MISS patients
MISS:12.32d Open: 15.51d	VAS : MISS vs OPEN: 1,16 vs 2,05, (Last Foll-Up ) ODI : 34.97 vs40.54 (1w)., 7.18 vs 11.40 (last) Neurological recovery : no difference	MISS is feasible and effective for unstable thoracolumbar fractures

The article in this systematic review also contains other things, which support this research. Junhi et al in a clinical trial study, measured using MRI on the cross-sectional area (CSA) of the multifidus muscle. Comparison of preoperative MRI and last follow-up, CSA multifidus decreased by only 7.6% ( $p < 0.05$ ) in the Wiltse group and there was less fat

infiltration compared with open surgery. CSA multifidus was reduced by 35.4% ( $p < 0.05$ ) in the typical open method group, and there was an increase in fat infiltration. At the last follow-up the VAS score on the MISS approach was lower than the open approach (0.9 vs 1.7).

A retrospective study by Wang et al, After 6 months of surgery the VAS score in

the PPSF group was lower than that of the OPSF (1.9 vs 3.1). similar results in the ODI measure (7.2 vs 16). However, at the last follow-up there were no significant differences in VAS scores, ODI, postoperative complications and neurologic recovery.

In the retrospective study of Zhang et al, the Relief of canal encroachment MISS vs. OPEN was 4.0% vs. 9.1. after more than 1 year of follow-up, the VAS score of the MISS approach was significantly lower than the open approach (1.4 vs 2.4). In addition, there was no significant difference in neurologic recovery in the two groups.

In Lee et al's study, perioperative, hemoglobin drop was significantly lower using the MISS approach than the open approach (12 g/L vs 21 g/L). however, the fluoroscopic dose was significantly higher in the MISS approach (34 mSv vs 4 mSv). There was no difference in Kyphoticangulation correction, but with loss of position greater with open surgery (28% vs 96%).

Afolabi et al in a retrospective study, percutaneous screw fixation (PSF) required 37% fewer blood transfusions than OPS. in this study, there was no significant difference between length of hospital stay, complications and mortality.

Comparative study conducted by Younus et al. There was no difference in the outcome of neurological recovery and complications. In this study the MISS group had significant patient satisfaction.

Wang et al<sup>11</sup>, In the MISS approach, the first week follow-up ODI was significantly lower in the MISS approach than in the open approach (34.97 vs 40.54). In the last follow-up, the VAS score (1.16 vs 2.05) and ODI (7.18 vs 11.40) were significantly lower on the MISS approach. There was no significant difference in postoperative complications and neurological recovery.

## DISCUSSION

Surgery is the treatment of choice for thoraco-lumbar fractures, especially in patients with severe posterior ligament injuries such as unstable fractures and type B and C AO's fracture classification.<sup>8</sup> Surgery aims to reduce the deformity, restore the canal anatomy and consolidate the vertebral fracture.<sup>6</sup> Open surgery is associated with iatrogenic soft tissue damage.<sup>22</sup> On the other hand, non-operative therapy may result in progressive kyphosis, greater discomfort and possible neurologic degeneration.<sup>23</sup>

Management of thoracolumbar fractures must consider the safety and benefit of surgery.<sup>7</sup> Not all patients can tolerate long operating times, more blood loss and paraspinal muscle injury due to open surgery.<sup>6</sup> The MISS approach has grown rapidly in the last decade because it is considered more useful and safer.<sup>13</sup> The principle of the MISS approach is the same as that of the open approach. the principle of this approach is decompression,

stabilization and correction of deformity, but accompanied by relaxation of soft tissue.<sup>24</sup>

The MISS approach has the advantage of low operative time and blood loss during intraoperatively. The early post operative MISS approach has the advantage of a less VAS score and a shorter hospital stay. At the time of the evaluation of at least one year, the vas score on the MISS approach was the same as for open surgery. In some circumstances, the vas score on MISS was better than that of open surgery after one year of evaluation. MISS has the same low risk of complications, low mortality, neurological recovery and correction of kyphotic angulation as the open approach.<sup>6</sup>

The MISS approach is a surgical method that uses small and deep incisions to minimize muscle damage.<sup>10,11,13</sup> MISS approach uses the assistance of a navigator and radiology to maximize a wide and deep field of view.<sup>13,25</sup> This results in a shorter operating time using the MISS approach.<sup>25</sup>

The MISS approach, the procedure is performed in a very small surgical field.<sup>13</sup> So that the dissection can be done in an area that is less vascularized and can avoid major vessels.<sup>26</sup> Thus, the MISS approach is considered to have a lower blood loss rate.<sup>12,27</sup>

A long incision is used in the open approach. The long incision results in trauma to the paraspinal muscles, ligament dissection and postoperative pain.<sup>10</sup> The paraspinal muscles are denervated, ischemic and atrophic due to surgery.<sup>22</sup>

Denervation and devascularization cause muscle degeneration which results in decreased strength due to atrophy.<sup>6,22</sup>

Multifidus muscle dysfunction due to open approach is the pathophysiology of chronic postoperative LBP.<sup>6</sup> In addition, chronic changes in the multifidus muscle can be a problem in daily activities.<sup>22</sup>

Using the MISS approach, the multifidus muscle injury was less severe.<sup>22,27</sup> Fan et al, in their study stated that minimal back pain was associated with less multifidus muscle atrophy and fat infiltration.<sup>28</sup> Fat infiltration can have a negative impact on muscle contractility. in this method the nerve damage is lower, so the incidence of neuralgia can be reduced.<sup>12</sup>

Due to the low VAS score, complications, muscle atrophy and the need for assistive devices, recovery and rehabilitation of patients with the MISS approach becomes easier and faster.<sup>6,11,12</sup> This implies that the hospital stay is relatively shorter.

Some patients with the open approach experienced longer treatment due to need for additional care.<sup>29</sup> The open approach can result in sufficient blood loss to cause hypovolemic shock.<sup>30</sup> In addition, complications from open approval are muscle damage that results in atrophy, thus prolonging the patient's recovery and rehabilitation.<sup>24</sup> Other complications that can arise are durotomy, neuralgia, DVT, infection, pleural effusion and hemothorax.<sup>31</sup> These complications require

treatment resulting in prolonged hospitalization.<sup>30</sup>

In several studies in this systematic review, the results of the evaluation are more than 1 year.<sup>15-21</sup> The MISS approach reduces the rate of complications during surgery, postoperative symptoms and improves the patient's quality of life.<sup>30</sup> No significant difference was found between MISS and Open approach after 1 year of evaluation.<sup>22</sup>

The MISS approach is suitable as an alternative to the open approach for the management of thoracolumbar fractures in all types of fractures.<sup>24</sup> This is because the MISS approach has many advantages and is just as effective as the open approach in the management of thoracolumbar fractures.<sup>7,22,31</sup> MISS approach can reduce morbidity and increase patient satisfaction in the management of thoracolumbar fractures.<sup>20</sup>

The limitations of this systematic review are the minimal number of studies

that match the criteria and the heterogeneity of the research. More indicators are needed to evaluate the further advantages of the MISS approach. In this review, the authors did not conduct further analysis to determine the estimated effect size between the MISS approach and the Open Approach. However, we provide some evidence that the MISS approach has advantages in the management of all types of thoracolumbar fractures. MISS may be useful in the management of thoracolumbar fractures which contraindicate open surgery as treatment.

## CONCLUSION

Based on the evidence presented in this systematic review, A minimally invasive approach provides an advantageous and safer to the management of all types of thoracolumbar fractures. In addition, the MISS Approach also provides a high level of patient satisfaction.

## REFERENCES

1. Sharif S, Shaikh Y, Yaman O, Zileli M. *Surgical Techniques for Thoracolumbar Spine Fractures: WFNS Spine Committee Recommendations. Neurospine. 2021;18(4):667-80.*
2. Fitschen-Oestern S, Scheuerlein F, Weuster M, Klueter T, Menzendorf L, Varoga D, et al. *Reduction and retention of thoracolumbar fractures by minimally invasive stabilisation versus open posterior instrumentation. Injury, Int. J. Care Injured 46S4. 2015;S63–S70.*
3. Li B, Sun C, Zhao C, Yao X, Zhang Y, Duan H, et al. *Epidemiological profile of thoracolumbar fracture (TLF) over a period of 10 years in Tianjin, China. The Journal of Spinal Cord Medicine. 2019;178-83.*
4. Laghrouche F, Prost S, Farah K, Graillon T, Blondel B, Fuentes S. *Minimally invasive treatment of thoracolumbar flexion-distraction fracture. Orthopaedics & Traumatology: Surgery & Research. 2019;105(2):347–50.*



5. Vu C, Gendelberg D. *Classifications in Brief: AO Thoracolumbar Classification System. Clinical Orthopaedics & Related Research.* 2020;478:434-40.
6. Pinheiro AC, Areias M, Oliveira C, Sousa CV, Silva LP, et al. *Percutaneous Fixation in the Treatment of Traumatic Thoracolumbar Fractures: A Current View of this Minimally Invasive Surgery. International Physical Medicine & Rehabilitation Journal.* 2018;3(3).
7. Byvaltsev VA, Kalinin AA, Polkin RA, Shepelev VV, Aliyev MA, Dyussebekov YK. *Minimally invasive corpectomy and percutaneous transpedicular stabilization in the treatment of patients with unstable injuries of the thoracolumbar spine: Results of retrospective case series. Journal of Craniovertebral Junction and Spine.* 2021;12:294-301.
8. Defino HLA, Costa HRT, Nunes AA, Barbosa MN, et al. *Open versus minimally invasive percutaneous surgery for surgical treatment of thoracolumbar spine fractures- a multicenter randomized controlled trial: study protocol. BMC Musculoskeletal Disorders.* 2019;20:397.
9. O'Toole JE, Kaiser MG, Anderson PA, et al. *Congress of Neurological Surgeons systematic review and evidence-based guidelines on the evaluation and treatment of patients with thoracolumbar spine trauma: executive summary. Neurosurgery.* 2019;84(1):2-6.
10. Yang P, Chen K, Zhang K, et al. *Percutaneous short-segment pedicle instrumentation assisted with O-arm navigation in the treatment of thoracolumbar burst fractures. Journal of Orthopaedic Translation.* 2020;21:1-7.
11. Yu JHY, Fridley J, Gokaslan Z, Telfeian A, Oyelese AA. *Minimally Invasive Thoracolumbar Corpectomy and Stabilization for Unstable Burst Fractures Using Intraoperative Computed Tomography and Computer-Assisted Spinal Navigation. World Neurosurg.* 2018;e1-e9.
12. Bordon G, Girona SB. *Assessment of related surgical complications of minimally invasive retropleural approach to the thoraco-lumbar spine. Rev Esp Cir Ortop Traumatol.* 2019;63:209--16.
13. Giorgi PD, Pallotta ML, Legrenzi S, Nardi M, Andrea M, Schirò GR. *Spinal cord compression in thoracolumbar burst fractures: application of high-definition three-dimensional exoscope in minimally invasive lateral surgery. European Journal of Orthopaedic Surgery & Traumatology.* 2022.
14. Cavanaugh D, Usmani MF, Weir TB, Camacho J, Yousaf I, Khatri V, Bivona L, et al. *Radiographic Evaluation of Minimally Invasive Instrumentation and Fusion for Treating Unstable Spinal Column Injuries. Global Spine Journal.* 2020;10(2):169-76.
15. Junhui L, Zhengbao P, Wenbin X, Lu H, Shengyun L, Shunwu F, Fengdong Z. *Comparison of pedicle fixation by the Wiltse approach and the conventional posterior open approach for thoracolumbar fractures, using MRI, histological and electrophysiological analyses of the multifidus muscle. European Spine Journal: Official Publication of the European Spine Society, the European Spinal Deformity Society, and the European Section of the Cervical Spine Research Society.* 2017;26(5):1506-1514.
16. Wang B, Fan Y, Dong J, Wang H, Wang F, Liu Z, Liu H, et al. *A retrospective study comparing percutaneous and open pedicle screw fixation for thoracolumbar fractures with spinal injuries. Medicine.* 2017;96(38):8104-9.

17. Zhang B, Zhou F, Wang L, Wang H, Jiang J, Guo Q, Lu X. A new decompression technique for upper lumbar fracture with neurologic deficit-comparison with traditional open posterior surgery. *BMC Musculoskeletal Disorders*. 2019;20(1):580-9.
18. Lee YC, Selby M, Zotti M, Roy D, Freeman B. Minimally invasive stabilization for thoracolumbar and lumbar fractures: A comparative study with short segment open Schanz screw constructs. *Journal of Spine Surgery*. 2019;5(1):13–18.
19. Afolabi A, Weir TB, Usmani MF, Camacho JE, Bruckner JJ, Gopinath R, Banagan KE, et al. Comparison of percutaneous minimally invasive versus open posterior spine surgery for fixation of thoracolumbar fractures: A retrospective matched cohort analysis. *Journal of Orthopaedics*. 2020;18(2):185–190.
20. Younus A, Kelly A, Lekgwara P. An institutional review of percutaneous stabilization versus open stabilization of unstable thoracolumbar fractures. *Interdiscip Neurosurg*. 2020;1:22-24.
21. Wang S, Duan C, Yang H, Kang J, Wang Q. Wiltse Approach Versus Conventional Transforaminal Interbody Fusion for Unstable Thoracolumbar Fracture with Intervertebral Disc Lesions. *Orthop Surg*. 2022; 14(4):694–703.
22. Pishnamaz M, Schemmann U, Herren C, Horst K, Lichte P, et al. Muscular changes after minimally invasive versus open spinal stabilization of thoracolumbar fractures: A literature review. *J Musculoskelet Neuronal Interact*. 2018; 18(1):62-70.
23. Joaquim AF, Schroeder GD, Patel AA, Vaccaro AR. Clinical and radiological outcome of non-surgical management of thoracic and lumbar spinal fracture-dislocations—a historical analysis in the era of modern spinal surgery. *J Spinal Cord Med*. 2020;43(1):3–9.
24. Camacho JE, Usmani MF, Strickland AR, Banagan KE, Ludwig SC. The use of minimally invasive surgery in spine trauma: a review of concepts. *J Spine Surg*. 2019;5(Suppl 1):S91-S100.
25. Schleicher P, Scholz M, Pingel A, et al. Minimal-invasive Techniken bei traumatischen Halswirbelsäulenverletzungen. *Unfallchirurg*. 2020;123:783–791.
26. Mikhail C, Pennington Z, Arnold PM, Brodke DS, Chapman JR, Chutkan N, Daubs MD, et al. Minimizing Blood Loss in Spine Surgery. *Global Spine Journal*. 2020;Vol. 10(1S): 71S-83S.
27. Gilbert F, Heintel MT, Jakubietz MG, Köstler H, et al. Quantitative MRI comparison of multifidus muscle degeneration in thoracolumbar fractures treated with open and minimally invasive approach. *BMC Musculoskeletal Disorders*. 2018;19:75.
28. Fan S, Hu Z, Zhao F, Zhao X, Huang Y, Fang X. Multifidus muscle changes and clinical effects of onelevel posterior lumbar interbody fusion: minimally invasive procedure versus conventional open approach. *Eur Spine J*. 2010; 19:316-24.
29. Ansar MN, Hashmi SM, Colombo F. Minimally invasive spine (MIS) surgery in traumatic thoracolumbar fractures: A single-center experience. *Asian J Neurosurg*. 2020;15:76-82.
30. Huang YY, Fu TS, Lin DY, Li YD, et al. Minimally Invasive Percutaneous Vertebroplasty for Thoracolumbar Instrumented Vertebral Fracture in Patients With Posterior Instrumentation. *Pain Physician*. December. 2021;24:E1237-E1246.
31. Walker CT, Xu DS, Jakub Godzik J, Turner JD, Uribe JS. Minimally invasive surgery for thoracolumbar spinal trauma. *Ann Transl Med*. 2018;6(6):102